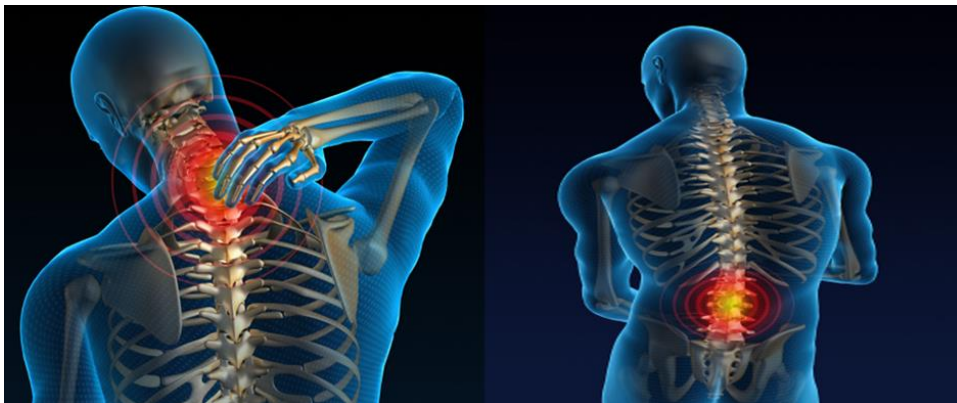


## SVT Ambidextrous Scanning Recommendations



It is well documented that there are risks of developing work related upper limb disorders (WRULD) and Work-Related Musculoskeletal Disorders (WRMSD) including repetitive strain injury, from performing ultrasound scans. WRMSD disorders can include those relating to muscles, tendons, ligaments and nerves and include back pain, neck or arm strains and diseases of the joints. The Health and Safety Executive reported that 470,000 workers in the UK suffer from WRMSD symptoms. All parts of the Healthcare workforce can be affected by WRMSD, it is one of the most common reasons for sickness absence in the NHS.



Vascular ultrasound investigations can be high risk for a number of reasons, including long duration and complexity, patient limitations with regards to optimal positioning for a scan, and having to tackle bilateral scans which ultimately require over reaching from desired scanning operator positions and optimal ergonomics. Often less experienced operators (for example those in training) will be more at risk due to potential longer scan duration, less developed skills/speed or awareness of their own posture/position, or experience in managing and optimising patient positioning. Those who have been scanning for a long time may be more prone to long term related issues due to 'wear and tear' and possibly arthritic or chronic MSK problems which may have arisen due to ongoing sub-optimal practice including poor ergonomics with posture, equipment and/or environment. Other factors may include poor ergonomics relating to the room layout and equipment ergonomic limitations.

### **Ambidextrous Scanning:**

You may wish to consider to 'share the load' by performing scans using both sides of our body, and learn ambidextrous scanning. It is most beneficial to learn this at the earliest opportunity in training, as often at this stage we are learning a 'new' skill with whatever hand we hold the probe. It is known

that around 10% of the population are left handed, however most scanning is taught with using a probe in the right hand. Therefore this document presumes that left handed scanning will be the 'new' hand. Incidentally, most right handed people will find using the keyboard and controls very easy with a right hand, whilst the left hand is learning to use a probe.

### **Starting to Scan Left Handed**

1. To introduce the left hand to the probe, it is often best to choose a simple scan such as an aorta or AAA measurement for gaining initial skills of left hand holding a probe steady in the transverse and longitudinal planes required to take caliper measurements.
2. Moving on to imaging a Common Carotid Artery in transverse view, and moving into a longitudinal plane, and learning gentle heel-toe probe manipulation where required to aid colour and Doppler angles. If you routinely perform carotid scans from the head end, then it is also natural to swap one hand to the other, as you scan each side.
3. The next obvious step is then moving the probe, in a longitudinal plane, along the whole length of SFA in a left leg, getting used to more smooth intuitive probe manipulations.
4. DVT compression scans may also be useful to consider for getting used to the left hand performing simple compressions such as throughout the femoral vein.

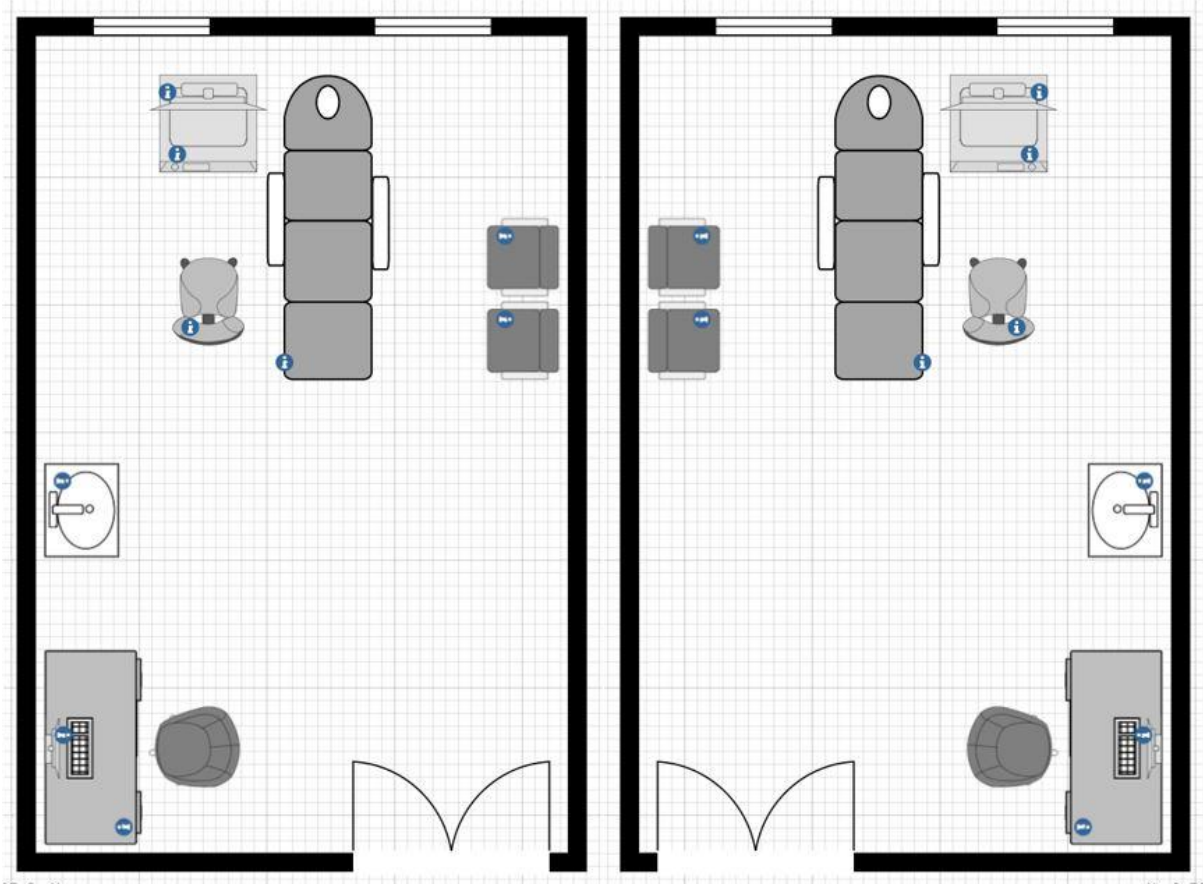
### **Room Set-up considerations**

We often hear that "We can't change the room to do left hand scans". There may be a few options to consider:

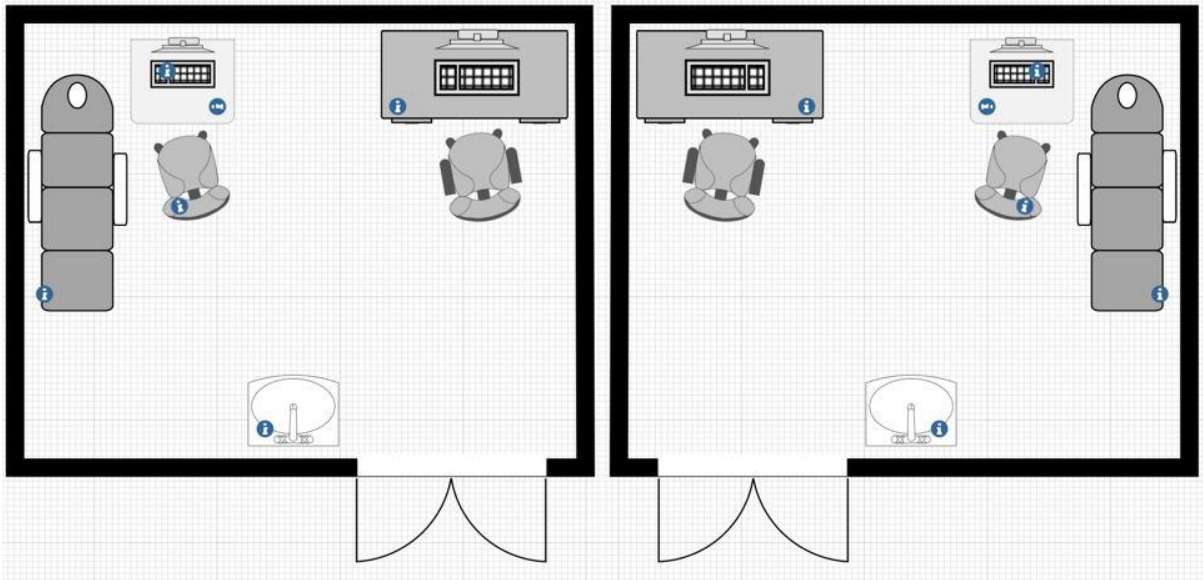
- Can the machine simply be moved from one end of a couch to another?
- Can the couch be moved to the other side of a room along with the machine?
- Can the couch be moved to the centre of the room to allow either side for machine setup?

### **Here are some layout options:**

Couch in the centre of a room:

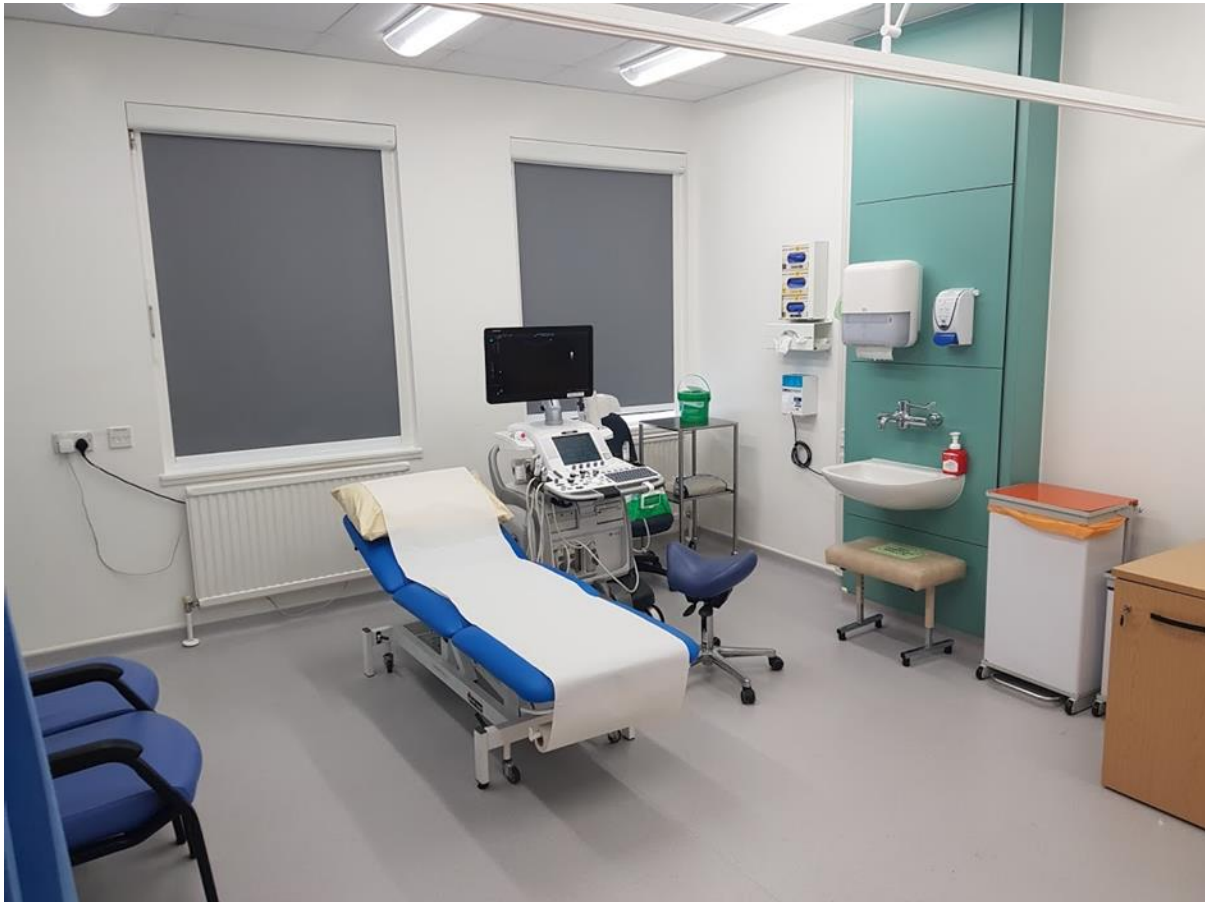

Couch against a wall:



Ideally you should aim to have a left room and a right room, with equal workloads (and staff rotation) allocated to each of these rooms. Additionally if booking allows, you would book a single

left leg arterial scan in the room set up for left handed scanning and vice versa for right. This way we can overcome the over-reaching required for bilateral arterial scans in these single leg scans.



### Benefits:

- **Reduce RSI & WRULD:**

This is the most obvious benefit as we will ideally share half of the work between hands for tricky probe manipulation, or even benefit from not allowing a keyboard/control panel arm be 'overused' especially if platforms do not offer the best ergonomics where we have to reach to the furthest part of the panel to reach our most frequently used controls.

- **Swapping hands during a scan:**

For example, during a leg dependant venous reflux scan, many people may benefit from positioning a leg where you are able to reach around the whole limb. There are often opportunities to swap the probe between hands as you follow the route of varicose veins.

- **Easier bedside scanning from either side of the patient:**

If we are equally happy with right and left side scanning, it makes the bedside scans much less challenging. Ideally you would set up a machine on the side of a specific assessment. But this is also useful in tricky situations where there is limited access to a particular side of a bed, for example due to other equipment, people or room layout issues – often in intensive care or theatre environments there may be these type of considerations.

- **Allows different room layouts which may not have been favourable previously:**

If you have always had that 'one room' which feels limited by inherent factors such as fixed things such as doors, windows, sinks, power supply etc, it may be possible to plan the room in a previously unconsidered option of layout by swapping left and right couch layout.

#### Risks:

- **Holding the probe with wrong orientation and acquiring images in incorrect orientation:**

Whichever hand is holding a probe, the convention is that the 'top' leading probe edge is pointing towards the heart (or head in the case of carotids), and towards the left of the screen in a longitudinal view, and the leading edge of the probe is to the left of the body and left on the image screen for the abdomen in a transverse view.

- **Getting right and left sides mixed up.**

This may happen if we are used to always starting a scan on a leg furthest away, or a neck etc. Therefore it is vital at an early stage of training to establish a specific routine, such as always scanning a right leg then left leg if you are doing bilateral scans. Or perhaps if you are very visual in the way you recall information, scan the furthest leg first (longest reach) then the closest one second – however this will be a different side leg being furthest away in each room. The former is the best fail-safe, as any image review or query if labelling is missing, if you have trained and stuck to a failsafe order of how to approach a bilateral investigation, the images will be in the set order. The routine will be the same no matter which 'hand' has performed the scan.

#### Useful Websites and Publications:

- AIUM Practice Principles for Work-Related Musculoskeletal Disorder, Journal of Ultrasound in Medicine, Volume 42, Issue 5, May 2023, Pages 955-1166  
<https://onlinelibrary.wiley.com/share/MUTIMQ4UEQBS66QBQ7IQ?target=10.1002/jum.16124>
- SCoR: The Society of Radiographers (SoR) and the British Medical Ultrasound Society (BMUS). Guidelines for Professional Ultrasound Practice. Revision 6  
<https://www.sor.org/learning-advice/professional-body-guidance-and-publications/documents-and-publications/policy-guidance-document-library/sor-and-bmus-guidelines-seventh-edition>
- Harrison G, Harris A. Work-related musculoskeletal disorders in ultrasound: can you reduce risk? *Ultrasound* 2015; **23**: 224– 230. <https://doi.org/10.1177/1742271X15593575>.
- Healthy Sonographer website. <https://healthysonographer.com/>.
- <https://www.england.nhs.uk/elective-care-transformation/best-practice-solutions/musculoskeletal/>
- <https://www.hse.gov.uk/msd/>